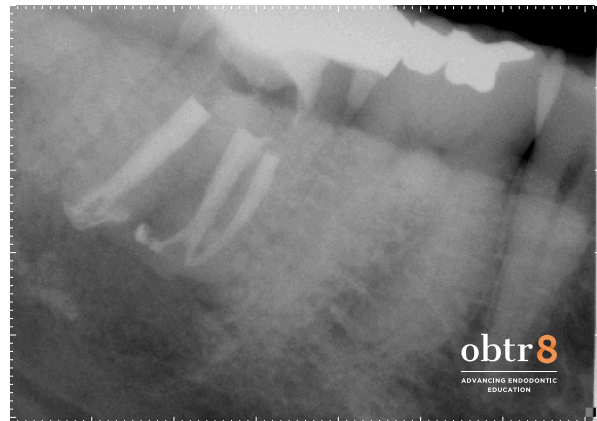
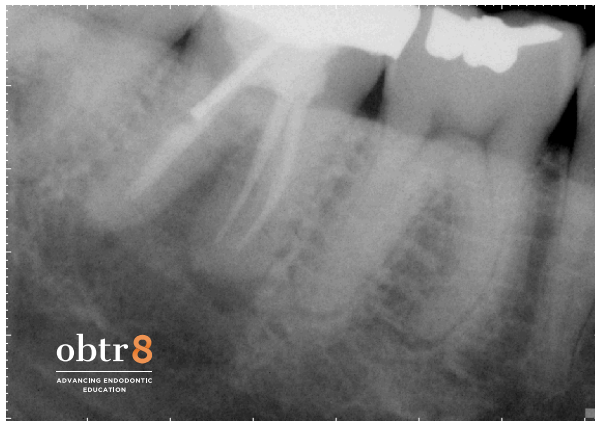

RETREATMENT OR APICAL SURGERY ?



DIAGNOSIS: # 31

**PULPAL: PREVIOUS ROOT CANAL TREATMENT
PERIAPICAL: ASYMPTOMATIC APICAL PERIODONTITIS**

INSTRUMENTATION: FOLLOWING REMOVAL OF THE POST AND PREVIOUS GUTTA PERCHA FILLING, THE SHAPE AND CLEANLINESS WERE ENHANCED WITH A PRIMARY WAVEONE FILE.

IRRIGATION: 5.25% SODIUM HYPOCHLORITE WITH QMIX 2 IN 1 AND ENDOACTIVATOR

OBTURATION: WARM VERTICAL DOWNPACK WITH THERMOPLASTIC GUTTA PERCHA BACKFILL

COMMENTS: THE SUCCESS OF ENDODONTIC TREATMENT IS DIRECTLY RELATED TO THE ELIMINATION OF BACTERIA FROM THE ROOT CANAL SYSTEM AND MORE SPECIFICALLY THE BACTERIAL BIOFILM. TREATMENT SHOULD BE DIRECTED TO THE OPTION THAT IS MOST LIKELY TO YIELD MAXIMUM CLEANLINESS WITH THE BEST SEAL OF THE CANALS.