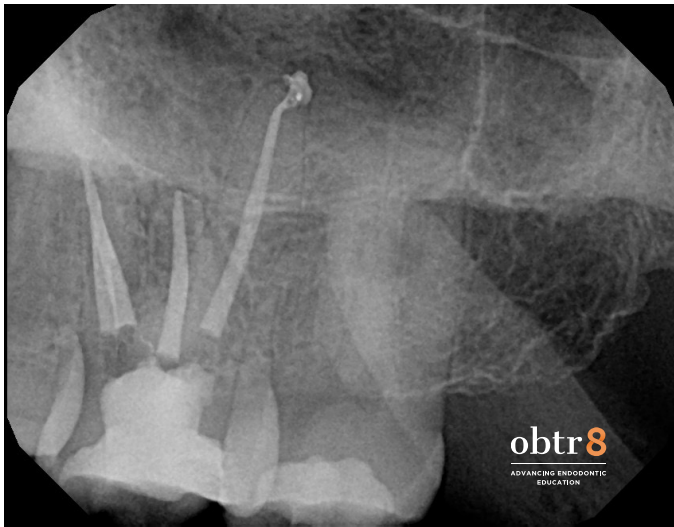
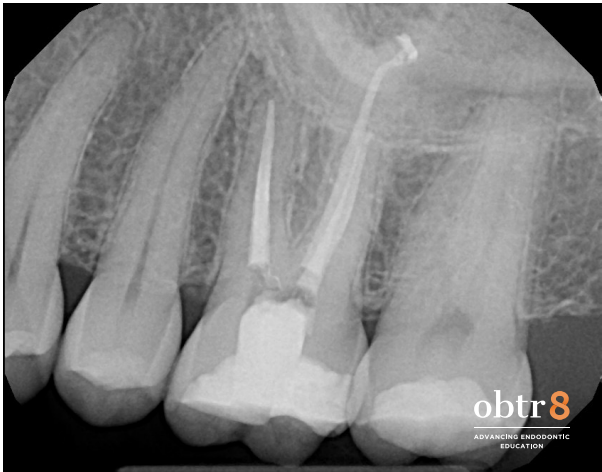
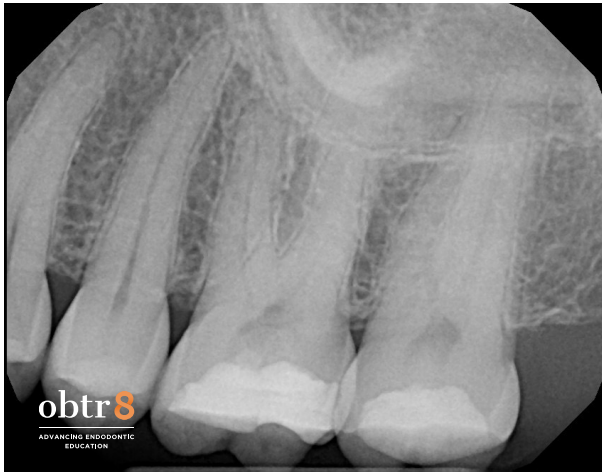
**WAVEONE GOLD:  
SIMPLICITY, EFFICIENCY, CONSISTENCY**



**DIAGNOSIS: # 14**

**PULPAL: NECROTIC**

**PERIAPICAL: SYMPTOMATIC APICAL PERIODONTITIS**

**INSTRUMENTATION:**

**ORIFICE OPENING: VORTEX ORIFICE OPENER 20 / 08**

**GLIDE PATH: 10 FILE AND PT NEXT # 1**

**FINAL SHAPE: WAVEONE GOLD PRIMARY IN ALL CANALS, WITH 40 AND 45  
HAND FILE AT APEX OF PALATAL ROOT**

**IRRIGATION: 5.25% SODIUM HYPOCHLORITE WITH QMIX 2 IN 1 AND ENDOACTIVATOR**

**OBTURATION: WARM VERTICAL DOWNPACK WITH THERMOPLASTIC GUTTA PERCHA  
BACKFILL**

**COMMENTS: THE ANGLED POST-OPERATIVE IMAGE SHOWS THE TWO CANALS IN THE  
MB ROOT JOIN TO EXIT A COMMON FORAMEN.**