Root Canal Shaping Using a Reciprocating File System

Category: Endodontics Created: Thursday, 14 February 2013 14:44 Written by David J. Landwehr, DDS, MS Print

INTRODUCTION

Biological and clinical success in endodontics is determined by the clinician's ability to eliminate bacteria.[1,2] This involves both the removal of bacteria during root canal instrumentation and the prevention of recontamination with a permanent restoration.[3,4] Rotary instrumentation has increased the ease of creating a more ideal shape in the main canals. However, clinical success rates, although highly variable depending on study design, have stayed relatively constant irrespective of instrumentation technique.[5,6] This may be due to microscopic anatomical complexity in teeth currently being treated that would have otherwise been extracted in the past. With this in mind, a significant percentage of the root canal system is not contacted with instruments during the shaping of the root canal[7] and it is impossible to physically remove all bacteria from microscopic channels present in many teeth.[8-10] As a result, it is mandatory that proper disinfection protocols be employed to ensure maximum cleanliness within the canal spaces. New methods for shaping and disinfection of the root canal are ever present in the marketplace.

This article will illustrate different uses of a new single-use, single-instrument mechanized shaping system: WaveOne (DENTSPLY Tulsa Dental Specialties) (Figure 1). Additionally, comparisons will be made between design features and final shapes using WaveOne and the time-tested ProFile Series 29 (DENTSPLY Tulsa Dental Specialties).

Figure 1. WaveOne Reciprocating Files (DENTSPLY Tulsa Dental Specialties) sizes are Small, Primary, and Large and available in 21-mm, 25-mm, and 31-mm lengths.

Figure 2. The EndoActivator System (DENTSPLY Tulsa Dental Specialties) is designed to sonically activate irrigants.

INSTRUMENT DESIGN

Although most WaveOne cases will be completed with a single instrument, there are 3 instruments available to accommodate different root canal anatomies. The primary file, used in the majority of cases, has a tip diameter of ISO 25 (0.25 mm) and an apical taper of .08 that decreases coronally to .055 to preserve tooth structure. The small file has a tip diameter of ISO 21 (0.21 mm) and a continuous taper of .06, while the large file is ISO 40 (0.40 mm) at the tip and .08 taper in the apical portion that decreases in the coronal portion like the primary file. Each of the file sizes is available in 21-, 25-, and 31-mm lengths. The tip is safe-ended and designed to follow the natural curve of the canal. The instruments are made of M-wire[11,12] and used in a crown down balanced force technique[13,14] in a reciprocating motor. To increase flexibility, the cross section of the instrument varies with a modified convex triangle at the tip (D1 to D8) and a convex triangle in the coronal portion (D9 to D16). The file moves in a counterclockwise direction with a reciprocating

motion.

In contrast to the WaveOne, Series 29 ProFiles have a constant taper (.04 or .06) and nonstandardized tip sizes. These instruments have a constant 29% increase between tip diameters. The constant percentage increase offers a smooth, progressive enlargement of the root canal system. These are the original Ni-Ti rotary instruments from DENTSPLY Tulsa Dental Specialties and have been available since the early to mid 1990s.

The ProFile 29 series has a U-file cross section which helps prevent the instruments from being pulled into the tooth. These files are designed to minimize transportation of the apex and remain centered in the canal. The ProFile 29 series instruments are made of standard SE Ni-Ti with flat radial land areas having a neutral rake angle that cuts equally over the canal circumference with a planing action. However, to create the ideal shape and cleanliness, 5 or more instruments may be needed.

Figure 3. QMix 2in1 Irrigating Solution (DENTSPLY Tulsa Dental Specialties) removes smear layer and disinfects following NaOCl.

TECHNIQUE

The same principles apply to WaveOne as other instrumentation methods. Profound anesthesia, rubber dam isolation, straight-line access, and a glide path to the apex are all required prior to using a WaveOne file. Although not necessary according to the manufacturer, opening the orifice may create a more direct path with less resistance to the apex. Additionally, removal of coronal dentin may increase accuracy in determining working length[15-17] and prevent extrusion of debris through the apex.

Most teeth will require a primary WaveOne file, but initial resistance with a 10 K-file will help determine the preferred WaveOne instrument. If 10 and 15 K-files go to the estimated working length with little or no resistance, then a primary WaveOne will likely be the instrument of choice. To the contrary, if significant filing is required with a 10 K-file to gain access to the apex, then a small WaveOne would be recommended. However, if a 20 K-file easily goes to working length, then a large WaveOne would be the preferred size. After the glide path is established and the WaveOne instrument is determined, sodium hypochlorite is placed in the chamber and the WaveOne is advanced into the canal. To prevent blocking the apex with debris and extruding dentin shavings and microbes through the apex, taking the WaveOne to length in a single pass is not recommended. Most canals will require approximately 3 passes to reach working length. After each pass, the canal should be rinsed of debris and apical patency verified. Additionally, the debris should be removed from the instrument flutes to ensure efficient cutting. Prior to shaping the apical third of the canal, verification of the final working length is recommended.[15] After the final shaping is complete, the taper will allow for excellent needle penetration for final rinsing and disinfection with sodium hypochlorite.18-20 To enhance debris removal, the EndoActivator (DENTSPLY Tulsa Dental Specialties) (Figure 2) can be used to sonically remove the smear layer with either QMix 2in1 Irrigating Solution (DENTSPLY Tulsa Dental Specialties) (Figure 3) or a combination of sodium hypochlorite and 17% EDTA followed by canal obturation with any technique of the clinician's choosing.

CASE REPORTS

Case 1

A 23-year-old female patient presented with a carious pulp exposure in tooth No. 3 from a recent filling (Figure 4). The tooth was anesthetized and isolated with a rubber dam. The mesial buccal (MB), distal buccal (DB), and palatal canals were cleaned with 10 and 15 K-files to establish a Glide path to the estimated working length and sodium hypochlorite was used to flush debris. A single ProTaper S1 (DENTSPLY Tulsa Dental Specialties) was used to remove the ledges of dentin over each canal orifice and create some initial shape short of the estimated working length. The precise working length was then determined using the Root ZX (J. Morita), and then the ProTaper S1 was taken to length in the 3 main canals. A WaveOne primary file was used in the MB and DB while a large WaveOne was used in the palatal canal. With sodium hypochlorite in the canals and chamber, the

WaveOne instrument was advanced in several millimeter increments with rinsing of debris after each pass until working length was reached.

CASE 1.

Figure 4. Radiograph shows a deep amalgam restoration in tooth No. 3.

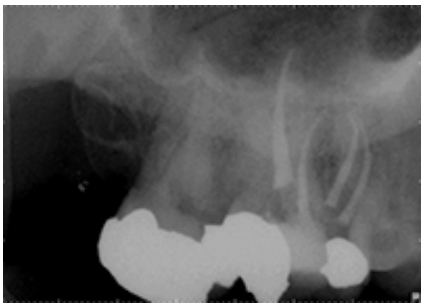

Figure 5. A WaveOne Primary file was used to create final shape.

Figure 6. System B Heat Source (Sybron Dental).

After the 3 main canals were shaped, a very small mesial lingual (ML) canal was identified under the microscope. This canal was opened with 10-40 K-files one to 2 mm below the pulpal floor and a 10 K-file was advanced into the canal. After the coronal two thirds had been opened, the hand files and the ProTaper S1 were able to advance to the 19-mm working length. Following the establishment of a glide path to the apex, the primary WaveOne was used to create the final shape to the root end (Figure 5). All canals were again rinsed with copious sodium hypochlorite and a final disinfection and smear layer removal was accomplished with QMix and the EndoActivator. The canals were dried and sealed with a System B Heat Source downpack (Sybron Dental) (Figure 6) and Obtura backfill (Obtura Spartan).

Case 2

A 45-year-old male presented with a history of a crack in tooth No. 18. A crown was recently fabricated and was in place with temporary cement because of continued symptoms (Figure 7). At the initial appointment, the quadrant was anesthetized and rubber dam isolation was achieved following removal of the crown. The inflamed pulp and several pulp stones were removed from the chamber and the canals were instrumented to working length with hand files to a size 15. To enlarge the initial glide path and ensure adequate removal of the dental pulp, ProTaper S1 and S2 files were used to working length. No internal crack was seen under the surgical microscope and calcium hydroxide was placed into the root canal system. This tooth was not completed in a single visit to better determine the long-term prognosis based on the initial behavior and function of the tooth. If the tooth remained pressure sensitive, the patient would likely have had it removed because of the presumed fracture on the root surface. However, the tooth was asymptomatic and functional upon return and the root canal treatment was completed.

CASE 2.

Figure 7. Radiographic examination of tooth No. 18 was unremarkable.

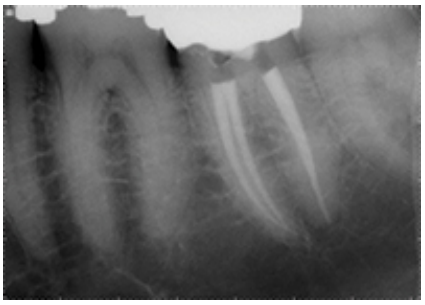

Figure 8. Radiograph showing slightly underfilled canals allowing room for a bonded core.

The area was again anesthetized and isolated and the WaveOne primary file was used to complete the shaping of the root canal. Sodium hypochlorite and QMix were used to complete the disinfection and removal of the smear layer with the EndoActivator. The canals were sealed with warm vertical condensation using System B and an Obtura backfill with AH plus sealer. The canals were underfilled slightly to allow room for a bonded core prior to placement of the permanent crown (Figure 8).

Case 3

A 30-year-old female presented on an emergency basis with a chief complaint of severe pain in the upper right quadrant from an irreversible pulpitis in tooth No. 3 (Figure 9). Following rubber dam isolation, the MB, DB, and palatal canals of tooth No. 3 were instrumented with 10 and 15 K-files to working length to establish a glide path and the initial shape was obtained with ProTaper files S1 and S2. Working length was established using the Root ZX, and copious sodium hypochlorite was used as an irrigant to flush dentin debris from the root canal system. The ML canal orifice was enlarged with a series of K-type hand files (size 10-40) one to 2 mm below the pulpal floor to remove a ledge of dentin and ensure straight-line access. A precurved 10 K-file was then used to gain access to the apex of the ML and a glide path was created. ProTaper S1 and S2 were used in all 4 canals to establish initial canal shape in the coronal two thirds of the canals. With sodium hypochlorite in the canals, Series 29 rotary instruments were used to create the final canal shape. The first shaping instrument was a .04 taper with a tip diameter of .360 (ProFile No. 6) followed by a .04 taper tip diameter .279 (ProFile No. 5). After the .04 taper instruments created the initial shape, two .06 taper instruments with the identical tip sizes as the .04 instruments were used to create the deep shape that allows maximum penetration of sodium hypochlorite to disinfect the root canal system. The smear layer was removed with 17% EDTA followed by sodium hypochlorite and filled with a System B downpack followed by Obtura backfill. The 2 canals in the MB root joined to exit a common foramen (Figure 10).

CASE 3.

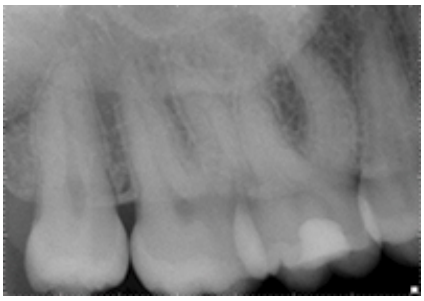

Figure 9. Radiographic examination revealed a deep restoration close to the pulp in

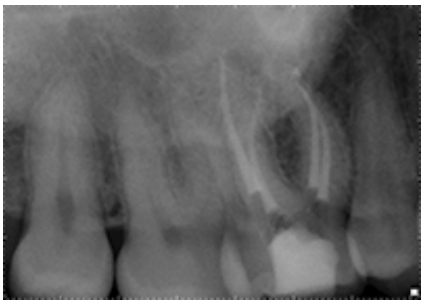

Figure 10. Radiograph showing the 2 canals in the mesial buccal root joined to

tooth No. 3.	exit a common foramen.

DISCUSSION

These cases illustrate different applications of the WaveOne technique and a single case instrumented with a hybrid technique of ProTaper and ProFiles. Although the final shapes obtained in each of these cases are similar, the number of instruments required to achieve the desired outcome is very different. Additionally, the technical complexity and time required to achieve the desired outcome with the hybrid technique greatly exceeds that of the WaveOne system.

As with any instrumentation system or canal enlargement technique, the WaveOne will not be ideal in all cases. The taper and tip diameter may preclude its use in very small, long canals. Additionally, the design features may also prevent its use in anterior teeth with excessively large canals. However, these types of cases will highlight the limitations of any instrumentation technique.

The initial cost of the reciprocating motor may prevent some practitioners from making a change to the WaveOne, but initial cost of the motor would likely pay for itself many times over with increased efficiency and productivity. Currently, there are 2 motors from DENTSPLY Tulsa Dental Specialties designed for use with WaveOne and conventional rotary systems: the e3 Reciprocating Torque Control Motor and the ProMark Endo Motor.

Ease of use and a small learning curve are the obvious advantages of the WaveOne technique. These WaveOne cases utilized only a single file to create the final apical shape after a glide path was established. In spite of the reciprocating motion, WaveOne instruments feel and cut like other rotary instrument systems. As a result, any clinician with experience doing rotary endodontics will likely make a seamless transition to this technique. The instruments come pre-sterilized and are single use, saving lab time as well as chair time. Single-use instruments eliminate any potential for cross-contamination between patients. Single-use design and the reciprocating motion also reduce the risk of instrument fatigue and file breakage.

CLOSING COMMENTS

This article demonstrated different uses of a new single-use, single-instrument mechanized shaping system. Although these cases were filled with warm vertical condensation, the shape obtained with this method would be amenable to any method of obturation. Moreover, the shape allows for excellent irrigation and ultimately, the most important criteria for clinical success, the elimination of bacteria.

References

1. Kakehashi S, Stanley HR, Fitzgerald RJ. The effects of surgical exposures of dental pulps in germ-free and conventional laboratory rats. *Oral Surg Oral Med Oral Pathol*. 1965;20:340-349.
2. Möller AJ, Fabricius L, Dahlén G, et al. Influence on periapical tissues of indigenous oral bacteria and necrotic pulp tissue in monkeys. *Scand J Dent Res*. 1981;89:475-484.
3. Yamauchi S, Shipper G, Buttke T, et al. Effect of orifice plugs on periapical inflammation in dogs. J Endod. 2006;32:524-526.
4. Ray HA, Trope M. Periapical status of endodontically treated teeth in relation to the technical quality of the root filling and the coronal restoration. *Int Endod J*. 1995;28:12-18.
5. Sjogren U, Hagglund B, Sundqvist G, et al. Factors affecting the long-term results of endodontic treatment. *J Endod*. 1990;16:498-504.
6. Salehrabi R, Rotstein I. Endodontic treatment outcomes in a large patient population in the USA: an epidemiological study. *J Endod*. 2004;30:846-850.
7. Peters OA, Schönenberger K, Laib A. Effects of four Ni-Ti preparation techniques on root canal geometry assessed by micro computed tomography. *Int Endod J*. 2001;34:221-230.
8. Siqueira JF Jr, Rôças IN, Favieri A, et al. Chemomechanical reduction of the bacterial population in the root canal after instrumentation and irrigation with 1%, 2.5%, and 5.25% sodium hypochlorite. *J Endod*. 2000;26:331-334.
9. Dalton BC, Ørstavik D, Phillips C, et al. Bacterial reduction with nickel-titanium rotary instrumentation.

J Endod. 1998;24:763-767.
10. Shuping GB, Ørstavik D, Sigurdsson A, et al. Reduction of intracanal bacteria using nickel-titanium rotary instrumentation and various medications. *J Endod*. 2000;26:751-755.
11. Johnson E, Lloyd A, Kuttler S, et al. Comparison between a novel nickel-titanium alloy and 508 nitinol on the cyclic fatigue life of Profile 25/.04 rotary instruments. *J Endod*. 2008;34:1406-1409.
12. Ye J, Gao Y. Metallurgical characterization of M-Wire nickel-titanium shape memory alloy used for endodontic rotary instruments during low-cycle fatigue. *J Endod*. 2012;38:105-107.
13. Roane JB, Sabala CL, Duncanson MG Jr. The "balanced force" concept for instrumentation of curved canals. J Endod. 1985;11:203-211.
14. Wu MK, Wesselink PR. Efficacy of three techniques in cleaning the apical portion of curved root canals. *Oral Surg Oral Med Oral Pathol Oral Radiol Endod*. 1995;79:492-496.
15. Berutti E, Chiandussi G, Paolino DS, et al. Effect of canal length and curvature on working length alteration with WaveOne reciprocating files. *J Endod*. 2011;37:1687-1690.
16. Davis RD, Marshall JG, Baumgartner JC. Effect of early coronal flaring on working length change in curved canals using rotary nickel-titanium versus stainless steel instruments. *J Endod*. 2002;28:438-442.
17. de Camargo EJ, Zapata RO, Medeiros PL, et al. Influence of preflaring on the accuracy of length determination with four electronic apex locators. *J Endod*. 2009;35:1300-1302.
18. Chow TW. Mechanical effectiveness of root canal irrigation. *J Endod*. 1983;9:475-479.
19. Ram Z. Effectiveness of root canal irrigation. *Oral Surg Oral Med Oral Pathol*. 1977;44:306-312.
20. Sedgley CM, Nagel AC, Hall D, et al. Influence of irrigant needle depth in removing bioluminescent bacteria inoculated into instrumented root canals using real-time imaging in vitro. *Int Endod J*. 2005;38:97-104.

Dr. Landwehr studied as an undergraduate at the University of Wisconsin-Madison and went on to earn his DDS at the University of Minnesota in 1994. From there he completed training in 2 dental specialties. First, he earned an MS degree and certificate in oral and maxillofacial pathology at The Ohio State University in 1997 and then completed specialty training in endodontics at the University of Michigan in 1999. Dr. Landwehr returned to Wisconsin in 1999 and has been in private practice since that time. He has presented case studies and research findings internationally. In addition, he has published several articles in various peer-reviewed journals and served as an evidence reviewer for the ADA. He is also chief of endodontics for the Meriter Hospital general practice residency program in Madison. He can be reached at obtr8@yahoo.com.

Disclosure: Dr. Landwehr is a consultant and lecturer for DENTSPLY Tulsa Dental Specialties, but received no compensation for writing this article and has no financial interest in any product mentioned herein.